Lecture 6 Anatomy د.احمد فاضل

Anatomy of the mouth

The Tongue

The tongue is a mass of striated muscle covered with mucous membrane. The muscles attach the tongue to the styloid process and the soft palate above and to the mandible and the hyoid bone below. The tongue is divided into right and left halves by a median fibrous septum.

Mucous Membrane of the Tongue

The mucous membrane of the upper surface of the tongue can be divided into anterior and posterior parts by a V-shaped sulcus, the sulcus terminalis. The apex of the sulcus projects backward and is marked by a small pit, the foramen cecum. The sulcus serves to divide the tongue into the anterior two thirds, or oral part, and the posterior third, or pharyngeal part. The foramen cecum is an embryologic remnant and marks the site of the upper end of the thyroglossal duct. Three types of papillae are present on the upper surface of the anterior two thirds of the tongue: the filiform papillae, the fungiform papillae, and the vallate papillae.

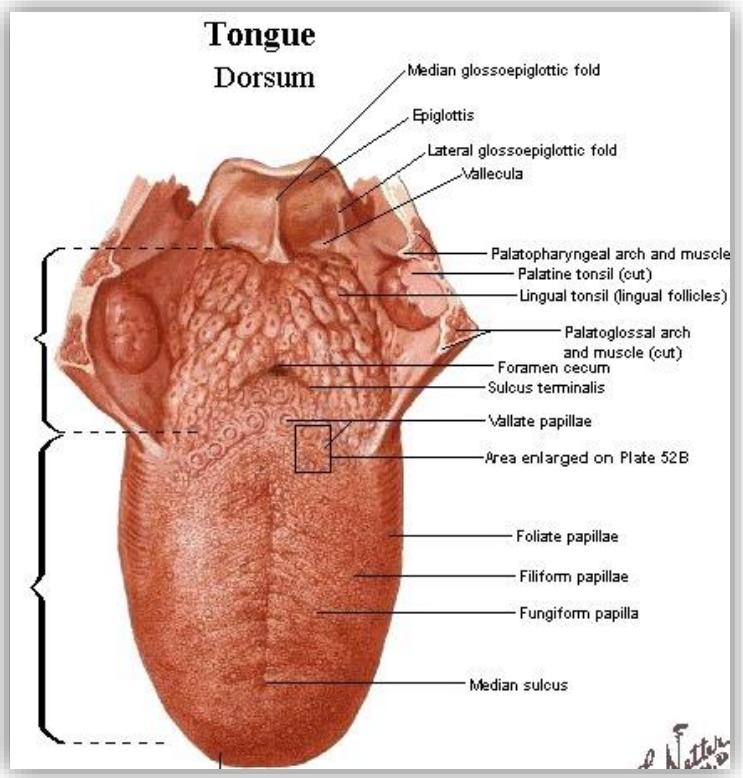

The mucous membrane covering the posterior third of the tongue is devoid of papillae but has an irregular surface, caused by the presence of underlying lymph

nodules, the lingual tonsil. The mucous membrane on the inferior surface of the tongue is reflected from the tongue to the floor of the mouth. In the midline anteriorly, the undersurface of the tongue is connected to the floor of the mouth by a fold of mucous membrane, the frenulum of the tongue. On the lateral side of the frenulum, the deep lingual vein can be seen through the mucous membrane.

Lateral to the lingual vein, the mucous membrane forms a fringed fold called the plica fimbriata.

Muscles of the Tongue

The muscles of the tongue are divided into two types: intrinsic and extrinsic.

Intrinsic Muscles

These muscles are confined to the tongue and are not attached to bone. They consist of longitudinal, transverse, and vertical fibers.

Nerve supply: Hypoglossal nerve

Action: Alter the shape of the tongue

Extrinsic Muscles

These muscles are attached to bones and the soft palate. They are the genioglossus, the hyoglossus, the styloglossus, and the palatoglossus.

Nerve supply: Hypoglossal nerve except the palatoglossus which supplied by pharyngeal nerve plexus.

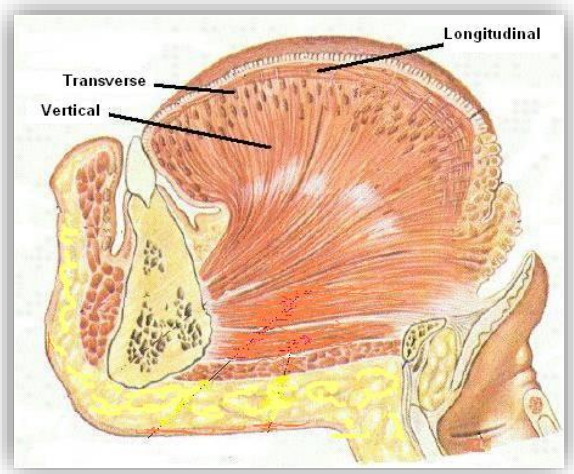

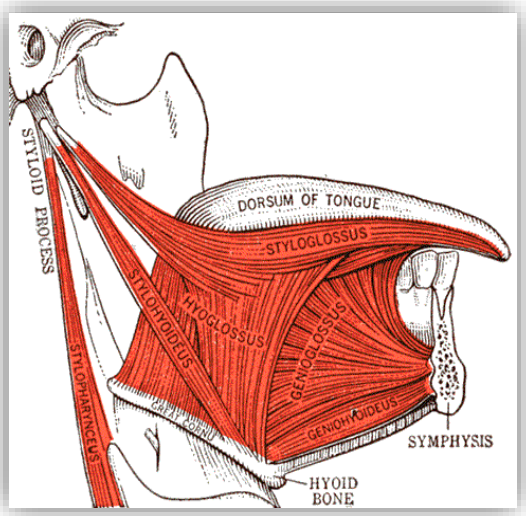

Blood Supply

The lingual artery, the tonsillar branch of the facial artery, and the ascending pharyngeal artery supply the tongue. The veins drain into the internal jugular vein.

Lymph Drainage

Tip: Submental lymph nodes
Sides of the anterior two thirds: Submandibular and deep cervical lymph nodes
Posterior third: Deep cervical lymph nodes

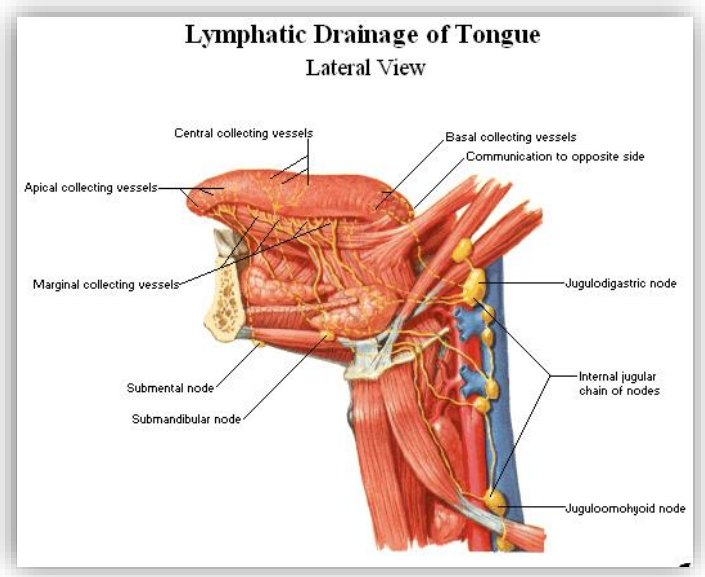

Sensory Innervation
Anterior two thirds: Lingual nerve branch of mandibular division of trigeminal nerve (general sensation) and chorda tympani branch of the facial nerve (taste)
Posterior third: Glossopharyngeal nerve (general sensation and taste)

Muscle	Origin	Insertion	Nerve Supply	Action
Intrinsic Muscles				
Longitudinal	Median septum and submucosa	Mucous membrane	Hypoglossal nerve	Alters shape of tongue
Transverse				
Vertical				
Extrinsic Muscles				
Genioglossus	Superior genial spine of mandible	Blends with other muscles of tongue	Hypoglossal nerve	Protrudes apex of tongue through mouth
Hyoglossus	Body and greater cornu of hyoid bone	Blends with other muscles of tongue	Hypoglossal nerve	Depresses tongue
Styloglossus	Styloid process of temporal bone	Blends with other muscles of tongue	Hypoglossal nerve	Draws tongue upward and backward
Palatoglossus	Palatine aponeurosis	Side of tongue	Pharyngeal plexus	Pulls roots of tongue upward and backward, narrows oropharyngeal isthmus

Movements of the Tongue

Protrusion: The genioglossus muscles on both sides acting together

Retraction: Styloglossus and hyoglossus muscles on both sides acting together
Depression: Hyoglossus muscles on both sides acting together
Retraction and elevation of the posterior third: Styloglossus and palatoglossus muscles on both sides acting together
Shape changes: Intrinsic muscles

The Palate
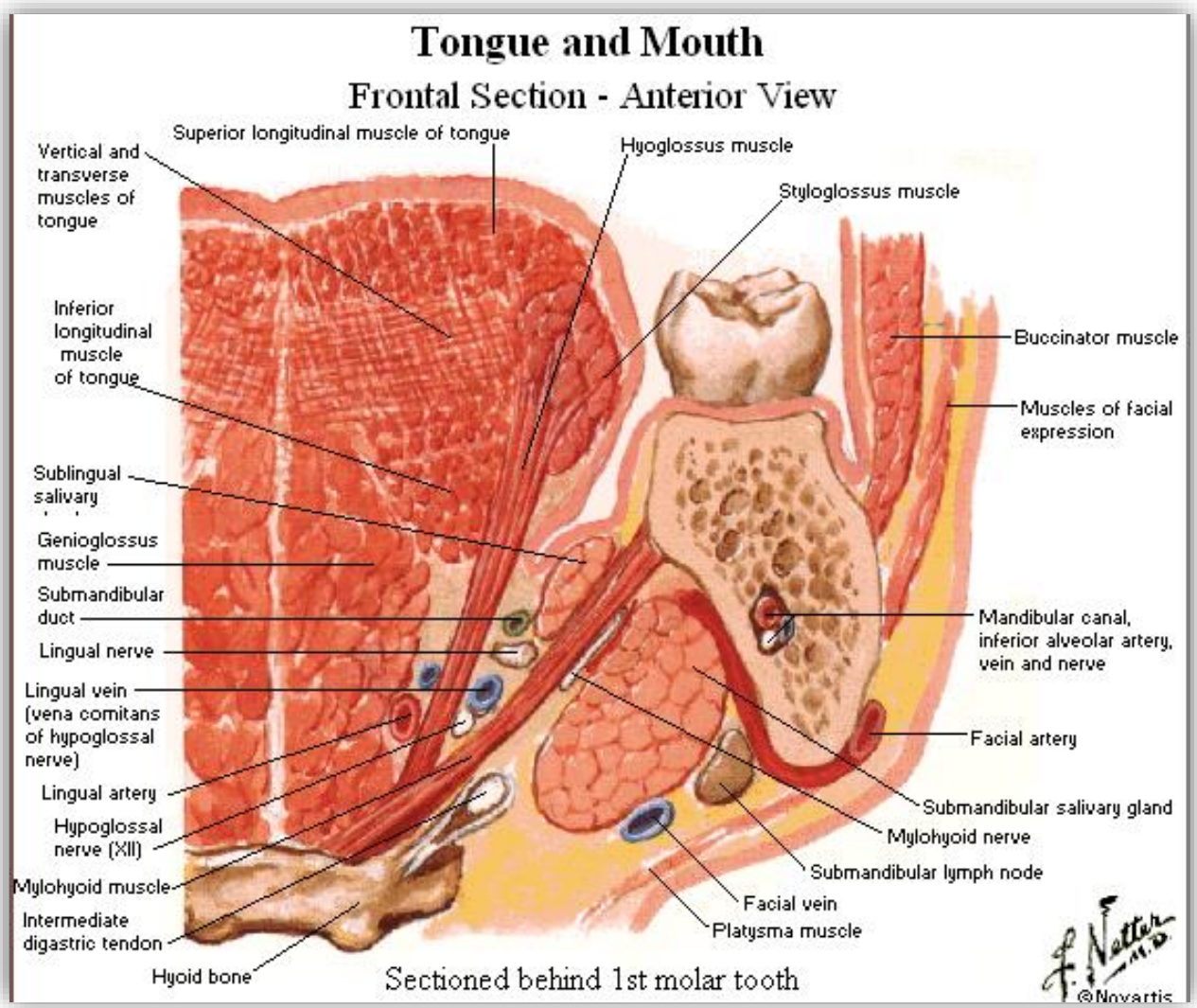
The palate forms the roof of the mouth and the floor of the nasal cavity. It is divided into two parts: the hard palate in front and the soft palate behind.